

Multisystem involvement is common in post-COVID-19 syndrome

A prospective clinical study evaluating patients 28–60 days after hospitalization for COVID-19 reveals increased cardio-renal inflammation, reduced lung function and poorer self-reported clinical outcomes in patients relative to that in control participants.

This is a summary of:

Morrow, A. J. et al. A multisystem, cardio-renal investigation of post-COVID-19 illness. *Nat. Med.* <https://doi.org/10.1038/s41591-022-01837-9> (2021).

Published online:

Published online: 23 May 2022

Publisher's note

Springer Nature remains neutral with regard to jurisdictional claims in published maps and institutional affiliations.

The problem

Self-reporting and population studies of the post-COVID-19 illness trajectory have found that residual signs and symptoms, such as fatigue, breathlessness, exercise intolerance, and adverse cardiovascular events leading to hospitalization and death, are common¹. However, prospective evaluations of disease pathogenesis and health status conducted at the outset of the COVID-19 pandemic are lacking, and clinical studies generally rely on the selective recall of patients – which potentially introduces selection bias². Some early studies lacked contemporary control participants matched for age, sex, ethnicity and comorbidity. Furthermore, disease classification is susceptible to ascertainment bias, as the COVID-19 illness trajectory may differ between hospitalized patients and community-based patients³. Accordingly, the pathological basis of post-COVID-19 syndrome (also known as long COVID) has not been elucidated objectively, which has led to an information gap that has underpinned uncertainty in management guidelines⁴.

The observation

We undertook a prospective, multicenter, longitudinal clinical study of objective measures of multisystem disease in patients hospitalized with COVID-19⁵. Serial blood biomarkers, digital electrocardiography and patient-reported outcome measures of health-related quality of life, physical function and psychological wellbeing were obtained in the hospital and at 28–60 days after discharge, along with computed tomography (CT)-based pulmonary and coronary angiography and cardio-renal magnetic resonance imaging (MRI) data. Longer-term clinical outcomes were assessed through the use of electronic health records. The primary outcome was the adjudicated likelihood of myocarditis; the adjudication procedure involved a panel of experienced cardiologists to limit the potential for bias, and panel reviews were undertaken according to a pre-specified charter and were informed by diagnostic criteria defined in international clinical guidelines. The control group consisted of patients hospitalized with non-COVID-19 illness, patients with recent unscheduled secondary care attendance or a scheduled outpatient clinical review, and volunteers with cardiovascular risk factors such as hypertension.

Compared with control participants, at 28–60 days after discharge, patients with COVID-19 showed increased incidence of cardio-renal involvement (Fig. 1) and hemostasis pathway activation; worse health-related quality of life, according to EQ-5D-5L surveys; worse anxiety and depression, according to the PHQ-4 questionnaire;

and diminished maximal oxygen utilization (and thus diminished aerobic exercise capacity). One in eight post-COVID-19 patients (13%) had an adjudicated diagnosis of myocarditis being highly likely. Unexpectedly, we found an inverse, multivariable association between blood concentration of hemoglobin A1c and the adjudicated likelihood of myocarditis. This result illustrates that multisystem illness severity due to COVID-19, rather than pre-existing disease, is one of the most important factors that drives post-COVID-19 syndrome. At follow-up (mean, 450 days), 15% of patients originally hospitalized for COVID-19 and 7% of control participants had been re-hospitalized or had died, with 68% of post-COVID-19 patients having received outpatient secondary care, compared with 26% of control participants.

The implications

Overall, we found that the COVID-19 illness trajectory includes persistent cardio-renal inflammation, hemostatic pathway activation and lung involvement. Our results demonstrate a link between the post-COVID-19 syndrome and multisystem disease, which partly explains the lingering impairments in patient-reported health-related quality of life, physical function and psychological well-being after COVID-19. The implication of multisystem injury pathways as mediators of post-COVID-19 syndrome should help to inform clinical guideline updates⁴, and the findings support the prioritization of targeted preventive therapy development for post-COVID-19 syndromes in hospitalized patients.

Limitations of the study are that most of the patients in our cohort were unvaccinated during enrollment and that the diagnosis of myocarditis was not based on the results of endomyocardial biopsies. Furthermore, selection and ascertainment bias were minimized but not eliminated, as patients who were deemed too frail to comply with the study procedures were not enrolled.

The participants will be invited to undergo longer term follow-up. We aim to assess persistent impairments in health status and to perform cardio-pulmonary exercise testing and stress perfusion cardiovascular MRI to provide objective measures of aerobic exercise capacity and myocardial blood flow. We will also assess multisystem disease pathways by quantifying circulating biomarkers using proteomics.

Colin Berry¹ and Kenneth Mangion²

¹British Heart Foundation Glasgow Cardiovascular Research Centre, University of Glasgow, Scotland, UK.

²NHS Queen Elizabeth University Hospital, Glasgow, Scotland, UK.

EXPERT OPINION

|| This prospective, multicenter, longitudinal cohort study detected continued multi-organ involvement 1–2 months after initial COVID-19, with significant numbers of individuals thought to have probable or likely myocarditis related to worse quality of life,

illness perception, anxiety and depression, and exercise capacity and physical activity. The data are a welcome addition to promote our understanding of the persistent effects from COVID-19.” **Sanjay H. Chotirmall, Lee Kong Chian School of Medicine, Nanyang Technological University, Singapore.**

FIGURE

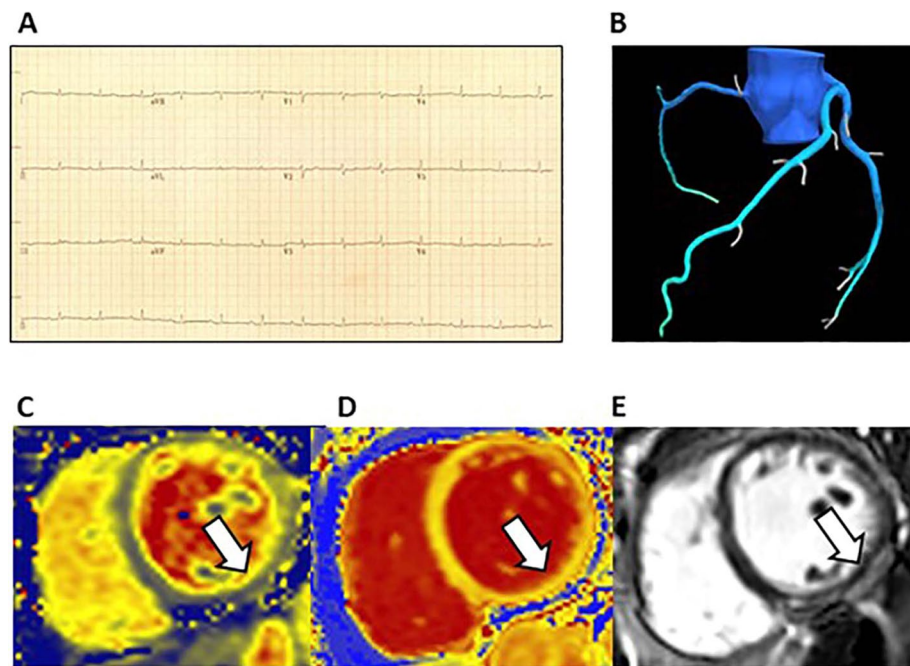


Fig. 1 | Myocarditis associated with acute COVID-19 infection. A 51-year-old woman received hospital care for COVID-19. A 12-lead electrocardiogram revealed T wave flattening laterally (a), and the peak concentration of high-sensitivity troponin I was increased (56 ng/L) (not shown). Chest CT and MRI were acquired 1 month after discharge from hospital. The possibility of coronary atherosclerosis was excluded by CT, and the values for fractional flow reserve derived from CT (FFR_{CT}) were normal (b). In the inferior wall of the left ventricle (white arrows, c–e), localized, mid-wall elevations in myocardial native T2 (c; 54 ms) and T1 (d; 1313 ms) relaxation times, indicative of acute myocardial inflammation, co-localized with late gadolinium enhancement (e). The adjudicated diagnosis was myocarditis secondary to COVID-19. © 2022, Morrow, A. J. et al., [CCBY 4.0](https://creativecommons.org/licenses/by/4.0/).

BEHIND THE PAPER

Our study was stimulated by controversy in the medical literature related to the incidence and clinical importance of myocarditis complicating COVID-19, and the limitations of prior studies related to case selection and control groups. The study involved a massive, multidisciplinary team effort undertaken in the most challenging conditions during the COVID-19 pandemic. Several of

our staff fell ill with COVID-19 during the course of the study. We also faced multiple logistical challenges in coordinating the workflow, and through teamwork and the willing support of our patients and staff, we succeeded in delivering this project. Targeted preventive strategies, including vaccination and pharmacological and lifestyle interventions, are warranted for long COVID. **C.B.**

REFERENCES

1. Al-Aly, Z., Xie, Y. & Bowe, B. High-dimensional characterization of post-acute sequelae of COVID-19. *Nature* **594**, 259–264 (2021).
This is a US population study of clinical events, including hospitalization and death, after COVID-19.
2. Puntmann, V. O. et al. Outcomes of cardiovascular magnetic resonance imaging in patients recently recovered from coronavirus disease 2019 (COVID-19). *JAMA Cardiol.* **5**, 1265–1273 (2020).
This early cardiovascular MRI describes myocardial involvement after COVID-19.
3. Blomberg, B. et al. Long COVID in a prospective cohort of home-isolated patients. *Nat. Med.* **27**, 1607–1613 (2021).
This paper describes the post-COVID illness trajectory in community (non-hospitalized) patients in Norway.
4. National Institute for Health and Care Excellence, the Scottish Intercollegiate Guidelines Network & the Royal College of General Practitioners. COVID-19 rapid guideline: managing the long-term effects of COVID-19. National Institute for Health and Care Excellence <https://www.nice.org.uk/guidance/NG188> (2021).
This publication provides expert guidance on the diagnosis and management of post-COVID-19 syndromes.
5. Mangion, K. et al. The chief scientist office cardiovascular and pulmonary imaging in SARS coronavirus disease-19 (CISCO-19) study. *Cardiovasc. Res.* **116**, 2185–2196 (2020).
This is the study design publication for our study.

FROM THE EDITOR

|| Understanding the sequela of post-acute COVID-19 is fundamental to the development of better management strategies to improve patient quality of life and care, as well as contributing to the as-yet-underdeveloped knowledge base of the long-term effects of SARS-CoV-2 infection. This work provides deep clinical phenotyping of patients with post-acute symptoms following hospitalization with COVID-19, and demonstrates persistence of multisystemic involvement and cardiac complications.” **Editorial Team, Nature Medicine**